

Otologic Manifestations in Samter's Syndrome

Marco Caversaccio^a Rudolf Häusler^a Arthur Helbling^b

^aDepartment of Otorhinolaryngology, Head and Neck Surgery, and ^bDivision of Allergology and Clinical Immunology, Inselspital, University of Bern, Bern, Switzerland

Key Words

Polyposis nasi · Samter's syndrome · Chronic otitis

Abstract

Objective: It was the aim of this study to investigate the prevalence of otologic manifestations in a cohort of Samter's syndrome patients (nasal polyps with chronic rhinosinusitis, aspirin intolerance and asthma). **Methods:** We analyzed a retrospective and prospective case review from 1995 to 2005, performed in the otorhinolaryngology outpatient clinic of a tertiary referral center. Ear history, clinical examinations, treatment and outcome were evaluated using office and hospital records in 23 cases. All subjects completed a questionnaire. **Results:** In 6 cases (26%), otological manifestations with ear pressure and conductive hearing loss occurred during an advanced stage of Samter's syndrome (>5 years after onset of the first nasal symptoms) partially responsive to systemic steroids. **Conclusion:** Recognition of the association between Samter's syndrome and otological disease is important (26% of the cases) because it could also be responsive to systemic steroids which prevent progression to irreversible hearing loss or infectious otomastoiditis.

Copyright © 2008 S. Karger AG, Basel

Introduction

Shortly after aspirin (acetylsalicylic acid, ASA) was developed by Felix Hoffmann, a German chemist, more than 100 years ago for the treatment of his father's arthritis, cases of severe attacks of asthma after ingestion of ASA have been described [1]. In 1922, the association of ASA sensitivity, aspirin-induced asthma (AIA) and nasal polyposis was described by Widal et al. [2], who were the first to make a desensitization. This full clinical picture of ASA intolerance was subsequently pointed out in the studies of Samter and Beers [3] and is currently commonly summarized as the 'Samter triad'. However, the triad can be incomplete, and nasal polyposis can be the first clinical symptom of ASA sensitivity. In patients with aspirin sensitivity, 36–96% have nasal polyps and up to 90% have radiographic changes affecting their paranasal sinuses. Concerning hereditary factors, HLA A1/B8 has been reported as having a higher incidence in patients with AIA. The incidence of aspirin hypersensitivity ranges from 0.6 to 2.5%, and in adults with asthma, from 4.3 to 21% [1, 4, 5]. Although the exact mechanism of ASA intolerance, as well as that behind therapy by ASA desensitization, remains unclear, evidence exists that the pathogenesis of ASA intolerance is not an IgE-mediated reaction. It is related to an abnormal metabolism of arachidonic acid, implicating the influence of the lipoxygenase and the cyclooxygenase pathways [5]. There is no in vitro test for the disorder, and diagnosis can only be estab-

lished by provocative challenges with aspirin or nonsteroidal anti-inflammatory drugs (NSAID). In addition to pharmacological options, ASA desensitization, followed by daily aspirin treatment, is a valuable therapeutic option in most patients with AIA, especially in those patients suffering from recurrent nasal polyposis or overdependence on systemic corticosteroids [5].

Otitis media with effusion (OME) has been reported to be frequently associated with allergic rhinitis and nasopharyngeal masses like nasal polyposis alone [6, 7]. However, in general, it is accepted that in such cases, OME is caused by Eustachian tube dysfunction secondary to swelling of the nasal mucosa or mucous stasis/polyps around the pharyngeal orifice of the Eustachian tube [7]. Inflammatory mediators in the nose and the nasopharynx produce blockage of the Eustachian tube through a number of mechanisms, which may include local injury or vascular or neurally mediated changes in the Eustachian tube opening pressure and in middle ear perfusion. If the blockage of the tube is prolonged like in cases of nasal polyposis without Samter's syndrome, changes in gas absorption, especially nitrogen, in the middle ear space accumulate and, with persistent underpressure, cause middle ear effusion. It should also be emphasized that bacterial and viral infections play a critical role in the development of acute otitis media and in the development of chronic histopathologic changes in the middle ear mucosa. In their textbook in 1967, Schambaugh et al. [8] described middle ear inflammation associated with allergic diseases as 'allergic otitis media'. They mentioned that one of the criteria for the diagnosis of 'allergic otitis media' was the presence of an extremely viscous mucoid effusion containing eosinophils, RANTES, eosinophilic cationic protein (ECP) or IgE. Recently, there have been some reports of patients with intractable OME or chronic otitis media in association with bronchial asthma and allergic rhinitis or nonallergic rhinopathy with eosinophils which could be the predecessor of Samter's syndrome [9–11].

The present study was carried out to investigate the prevalence of otologic disorder in a cohort of patients with Samter's syndrome.

Material and Methods

In this study, we included 23 patients (14 females and 9 males, mean age 54 years) with Samter's syndrome from 1995 to 2005 [12]. All patients had a long history of perennial and persistent asthma (>90% with more than 5 episodes after ASA/NSAID ingestion) and complained of a mainly chronic stuffy nose with

chronic rhinosinusitis. Nineteen patients also presented polyps and 14 underwent functional endoscopic sinus surgery; in 3 cases, only polypectomy was performed. Nasal passages were treated with different topical (intranasal) corticosteroid sprays (n = 23). In addition, different anti-inflammatory inhalants for the lungs (n = 15), or oral prednisone (n = 2) and leukotriene receptor antagonists (n = 5), have been used. A questionnaire with emphasis on otologic symptoms as well as labyrinth disorders was mailed to the patients. No genetic or histological middle ear mucosa analysis was performed.

The following examinations were conducted to clarify the clinical characteristics of the patients: inhalative bronchial provocation test with lysine-acetylsalicylate (n = 4); skin prick tests with common aeroallergens (Allergopharma™, Reinbek, Germany); serum analysis, including total IgE (Phadia, Uppsala, Sweden), eosinophils and ECP (Phadia); routine otorhinolaryngological examination, including otomicroscopy and nasopharyngeal endoscopy; CT scan of the sinuses (n = 23) and temporal bone (n = 6); histology of the nasal mucosa or polyp (n = 17), and pure-tone audiometry/tympanometry (n = 6).

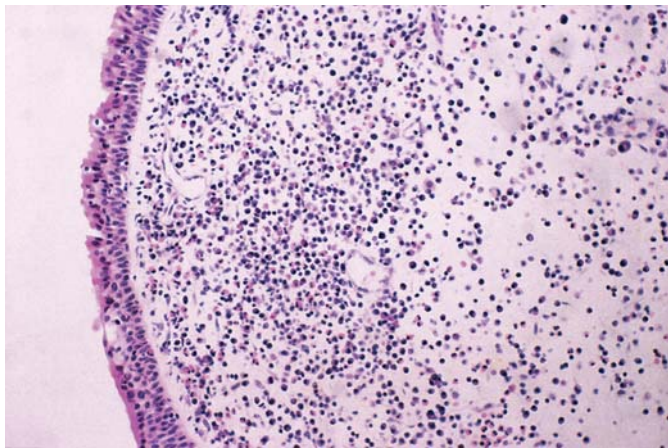
Informed consent was obtained from every patient, in keeping with the mandate of the Declaration of Helsinki, but the study was classified as exempt by the local institutional review board.

Results

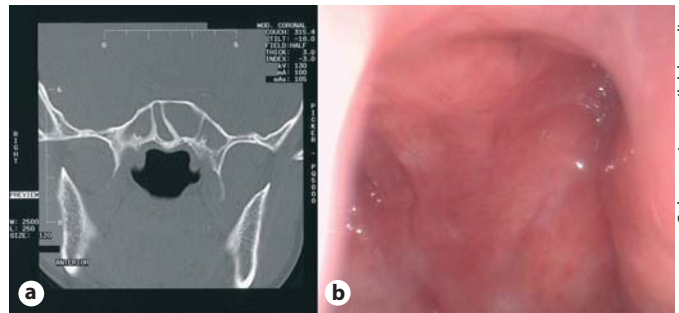
In 19 cases of suspected Samter's syndrome, the history of an aspirin or NSAID intolerance in the context with severe asthma and chronic rhinosinusitis was sufficient for the diagnosis. The inhalative lysine-acetylsalicylate provocation test was positive in each of the 4 patients (in whom the history for Samter's syndrome was not conclusive). Skin prick tests were positive in 9/23 patients (39%; pollen, n = 7; fungi, n = 2). The total IgE level was above the reference value of 70 kU/l in 12/23 subjects. Blood eosinophils were increased in 7/23 (>0.4 g/l) and ECP was elevated in 12/23 patients (>16 µg/l). However, these results must be cautiously interpreted because some tests were performed under local or even systemic corticoid therapy. CT scans of the paranasal sinuses (n = 23) revealed an obstructed and thickened mucosa in the ethmoid and maxillary sinuses in all patients. Histological results from functional endoscopic sinus surgery/polypectomy (n = 17) showed the eosinophils as dominant infiltrating cells in the submucosa of all nasal polyps (fig. 1).

Eustachian Tube

Based on the Eustachian tube function analysis with compliance and pressure level of tympanometries, the Eustachian tube function was poor in 6 cases (26%). The otoscopic findings on Valsalva maneuver showed a patu-



Color version available online



Color version available online

Fig. 2. Coronal CT scan of the entrance of the Eustachian tube with endoscopic view. The sphenoid sinus is filled with secretions (a), but no polyps are visible in the rhinopharynx. Secretions are visible on the orificium on the left side (b).

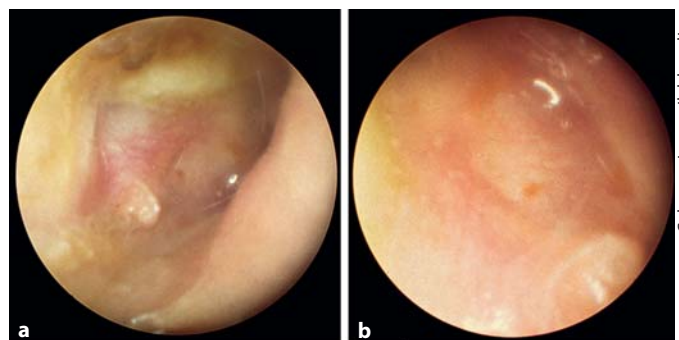
Fig. 1. Biopsy and histology from a middle ear mucosa polyp. In the stroma, eosinophils are visible. HE (original magnification $\times 165$).

lous tube. The mucosa around the pharyngeal orifice of the Eustachian tube seems macroscopically inflamed without direct growth of polyps, but with secretions (fig. 2). Polyps could be seen in the ethmoid or sphenoidoethmoidal recess, but it seems that the lymphatic tissue of the torus tubarius does not permit the growth of polyps.

Ear Symptoms

All 6 patients (4 males, mean age 57 years; 2 females, mean age 54 years) with otologic transmission disorders complained of ear fullness, hearing loss, autophonia ($n = 1$) and were diagnosed as having OME (fig. 3). Three of 6 patients had unspecific vertigo with normal caloric values and normal Hallpike maneuvers. In the remainder of the analyzed patients, 8 presented a sensory neural hearing loss in the audiometric high frequencies, and in 3 patients, no peripheral vertigo was found. We think that the sensory neural hearing loss was a sign of presbycusis rather than an infiltration of eosinophil-derived toxic products of the inner ear.

All 6 patients had received various treatments (topically applied nose corticoid spray, corticoid lung inhalation spray, alpha-sympathomimetic nasal drops, disinfected and corticoid-containing ear drops) performed by otorhinolaryngologists before presenting at our hospital. The findings on the temporal bone CT ($n = 6$) (fig. 4) showed a filled mastoid, and in the tympanic cavity, ossification of the bone. The pure-tone audiograms revealed a conductive hearing loss (mean average of 20 dB at 1,000 Hz). On average, the otologic manifestation was



Color version available online

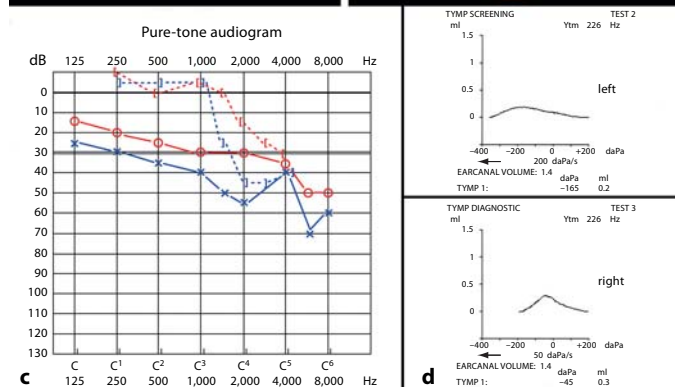


Fig. 3. Two thickened and inflamed ear drums (a right side; b left side). Conducted hearing loss in the pure-tone audiogram (c), and diminished compliance and negative pressure on the tympanogram (d).

seen >5.2 years (4.1–11.3 years) after the first nasal symptoms. Bilateral or unilateral perforation of the eardrum was present in 2 patients. Three patients had granular tissue arising from the middle ear mucosa protruding through the eardrum, unilaterally or bilaterally. In the 6 cases with otologic manifestations, a treatment with low-

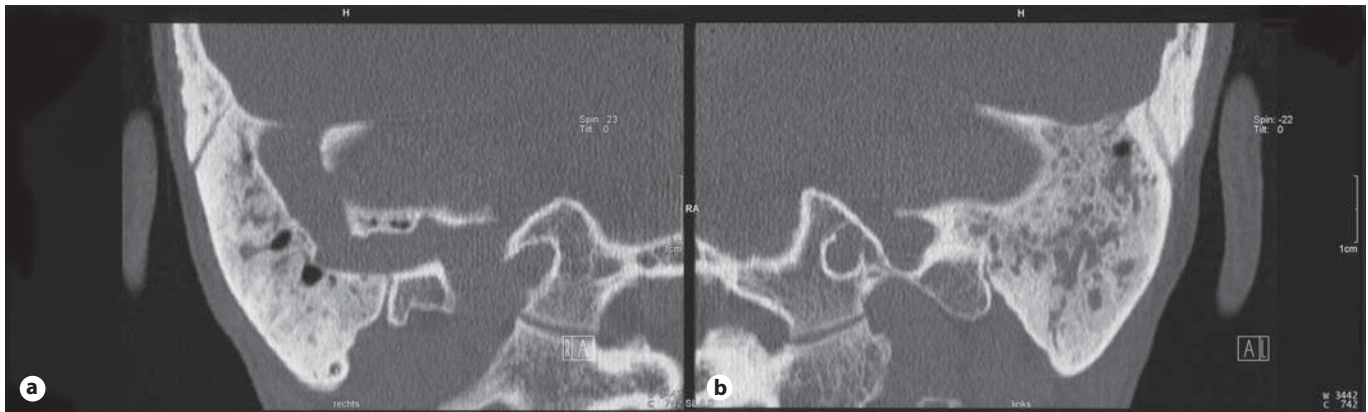


Fig. 4. Coronal CT scan of the temporal bone. The mastoid cavity is filled with secretions, and a chronified sclerotic bony structure is visible on both the right (**a**) and the left (**b**) side.

dose cortisone (5 mg/day) was initiated, and topical antibiotics containing corticosteroids (Otosporin™, GSK) were given for 5 days (n = 3) in cases of chronic otitis media. In all 6 patients, oral prednisone (20 mg/day for 14 days with decreasing doses) was administered with an improvement in hearing (10 dB), but in 3 cases, a grommet was necessary on one side, in 2 cases, on both sides, and in 1 case, a conservative mastoidectomy was performed. A hearing aid was necessary in 1 case. In 2 cases, a desensitization treatment with aspirin (1.15 g daily) was started with a partial satisfactory result, also for the ear symptoms, but only after 1 year.

A statistical analysis of the correlation between the CT and the hearing loss or correlation with the rhinoendoscopic view of the entrance to the Eustachian tube was statistically nonsignificant.

Discussion

Although the cause of otologic disorders is multifactorial, one of the most important causes, without doubts, is Eustachian tube dysfunction [7]. Eustachian tube function has been reported to deteriorate in case of an allergic inflammation of the nose [7]. Various mediators released by mucosal mast cells and other inflammatory cells in the nose and nasopharynx cause obstruction of the Eustachian tube, and finally lead to OME. The middle ear becomes filled with mucoid material containing eosinophils and the eardrum becomes thickened. This could be the consequences of tubal and tympanic mucosa involvement. Additionally, sniffing (negative pressure) could also contribute to OME, often associated with secretions

in the nose. Matsutani et al. [13] designated this new entity as 'eosinophilic otitis media' because some patients failed to show evidence of a type I allergy, in spite of the presence of many eosinophils in the middle ear effusion.

The present study revealed that in our patients, the pharyngeal orifice of the Eustachian tubes was not markedly edematous, and the Eustachian tube dysfunction was not always obstructive but sometimes patulous. However, in the AIA syndrome, we think that an active eosinophilic inflammation may occur in the entire respiratory tract including the middle ear [1, 5, 6]. Although the pathogenesis of eosinophilic accumulation of the tissues in these patients remains to be clarified, some 'allergic' predisposition may be responsible for the eosinophilic inflammation. Eosinophils are proinflammatory cells that are normally found in the circulatory system. They are stimulated to extravasate into tissues by chemoattractants produced by various inflammatory cells, epithelial cells and fibroblasts. Immunohistochemical studies have revealed that most eosinophils in the middle ear are EG2 positive and are activated after cell degranulation and the release of mediators such as ECP. ECP has the potential to cause epithelial cell toxicity and injury to the middle ear epithelium [11]. Although the mechanism of the underlying eosinophil accumulation in the middle ear remains unclear, cytokines and chemokines such as IL-3, granulocyte macrophage colony-stimulating factor, IL-5, transforming growth factor and RANTES released from activated eosinophils perpetuate the inflammatory process [14]. It also remains unclear if eosinophil-derived toxins could have a direct effect on inner ear destruction. Further studies are required to elucidate the mechanism

underlying eosinophilic accumulation in the middle ear and possible inner ear damage. It is also suggested that other antigenic materials such as bacteria, viruses and fungi may have invaded the middle ear via the Eustachian tube or through an eardrum perforation, causing eosinophilic inflammations in patients with a strong allergic predisposition. Patulous Eustachian tubes could allow antigenic materials to easily enter the middle ear.

At present, there is no effective treatment of the ear symptoms. Systemic administration of steroids could help transitionally. Additionally, topical steroids applied intranasally or ear drops containing steroids (betamethasone) and antibiotics could be administered. The role of antileukotrienes in the treatment of this inflammatory process remains unclear. Intratympanically applied steroids have direct effects on the tympanic mucosa and the tympanic orifice mucosa of the auditory tube. The clearance or drainage function of the Eustachian tube may contribute to good results. Tympanoplasty is contraindicated until the factor X of the disease is not recognized and controlled [8]. The present study shows that the de-

terioration in bone conduction hearing level was observed particularly in patients having persistent eardrum perforation with granular tissue formation in the mesotympanum. In these cases, inflammatory cells also have the possibility of entering into the inner ear through the round window membrane and cause inner ear damage. Recently, a new drug named ramatroban, a potent thromboxane A2 receptor antagonist, applied 150 mg/day post-operatively, has been shown to successfully treat eosinophilic otitis media [15]. Until now, no data exist with ASA-desensitized patients and the effect of such a treatment on the OME as well as progression of hearing loss [16]. Further clinical studies are necessary to elucidate the treatment possibilities.

In conclusion, the recognition of the association between Samter's syndrome and otological disease is important (26% of the cases) because it could also be transiently responsive to systemic steroids, which prevent progression to irreversible hearing loss or infectious otomastoiditis.

References

- 1 Pfaar O, Klimek L: Aspirin desensitization in aspirin intolerance: update on current standards and recent improvements. *Curr Opin Allergy Clin Immunol* 2006;6:161-166.
- 2 Widal MF, Abrami P, Lenmoyez J: Anaphylaxie et idiosyncrasie. *Presse Med* 1922;30:189-192.
- 3 Samter M, Beers RF: Intolerance to aspirin. Clinical studies and consideration of its pathogenesis. *Ann Intern Med* 1968;68:975-983.
- 4 Hedman J, Kaprio J, Poussa T, Nieminen MM: Prevalence of asthma, aspirin intolerance, nasal polyposis and chronic obstructive pulmonary disease in a population-based study. *Int J Epidemiol* 1999;28:717-722.
- 5 Szczeklik A, Stevenson DD: Aspirin-induced asthma: advances in pathogenesis, diagnosis, and management. *J Allergy Clin Immunol* 2003;111:913-921.
- 6 Nagamine H, Iino Y, Kojima C, Miyazawa T, Iida T: Clinical characteristics of so called eosinophilic otitis media. *Auris Nasus Larynx* 2002;29:19-28.
- 7 Bernstein JM: Role of allergy in Eustachian tube blockage and otitis media with effusion: a review. *Otolaryngol Head Neck Surg* 1996;114:562-568.
- 8 Schambaugh GE, Glasscock ME: *Surgery of the Ear*, ed 2. Philadelphia, Saunders, 1967, pp 210-211, 222, 255-256, 272.
- 9 Gamble JE, Bizal JA, Daetwyler EP: Otitis media and chronic middle ear effusion in asthmatic pediatric patient. *Ear Nose Throat J* 1992;71:397-399.
- 10 Morinaka S: Allergic otitis media with gelatinous mucoid fluid containing eosinophils. *Otolaryngol Head Neck Surg* 1996;114:665-668.
- 11 Hurst DS, Fredens K: Eosinophil cationic protein in mucosal biopsies from patients with allergy and otitis media with effusion. *Otolaryngol Head Neck Surg* 1997;117:42-48.
- 12 Fricker M, Caversaccio M, Müller UR, Pichler W, Helbling A: Morbus Widal: Nasenpolypen, Asthma bronchiale und Aspirin-Intoleranz. *Praxis* 2001;90:143-150.
- 13 Matstutani S, Kobayashi T, Takasaka T: Eosinophilic otitis media. *Otolaryngol Head Neck Surg Tokyo* 1995;67:712-713.
- 14 Iino Y, Nagamine H, Yabe T, Matstutani S: Eosinophils are activated in middle ear mucosa and middle ear effusion of patients with intractable otitis media associated with bronchial asthma. *Clin Exp Allergy* 2001;31:1135-1143.
- 15 Wada T, Uemaetomari I, Murashita H, Tobita T, Tsuji S, Tabuchi K, Okubo H, Hara A: Successful treatment of eosinophilic otitis media using ramatroban: report of two cases. *Auris Nasus Larynx* 2006;33:455-460.
- 16 Lee JY, Simon RA, Stevenson DD: Selection of aspirin dosages for aspirin desensitization treatment in patients with aspirin-exacerbated respiratory disease. *J Allergy Clin Immunol* 2007;119:157-164.

Reproduced with permission of the copyright owner. Further reproduction prohibited without permission.